

PennHIP Report

Referring Veterinarian: Dr Thomas Hitzeman

Clinic Name: Auburn Hills Animal Hospital

Email: dr.tom@auburnhillsanimalhospital.com

Clinic Address: 3120 County Road 36
Auburn, IN 46706

Phone:

Fax: (260) 925-6938

Patient Information

Client: Eshbach, Mike

Tattoo Num:

Patient Name: Pheasant Run Ice Man "Beau"

Patient ID: Eshbach&Pheasant Run Ice Man &Beau

Reg. Name: Pheasant Run Ice Man

Registration Num: 5538613404

PennHIP Num: 187224

Microchip Num: 956000015093125

Species: Canine

Breed: GOLDEN RETRIEVER

Date of Birth: 19 Nov 2022

Age: 18 weeks

Sex: Male

Weight: 33 lbs/15 kgs

Date of Study: 30 Mar 2023

Date Submitted: 05 Apr 2023

Date of Report: 05 Apr 2023

Findings

Distraction Index (DI): Right DI = 0.35, Left DI = 0.35.

Osteoarthritis (OA): No radiographic evidence of OA for either hip.

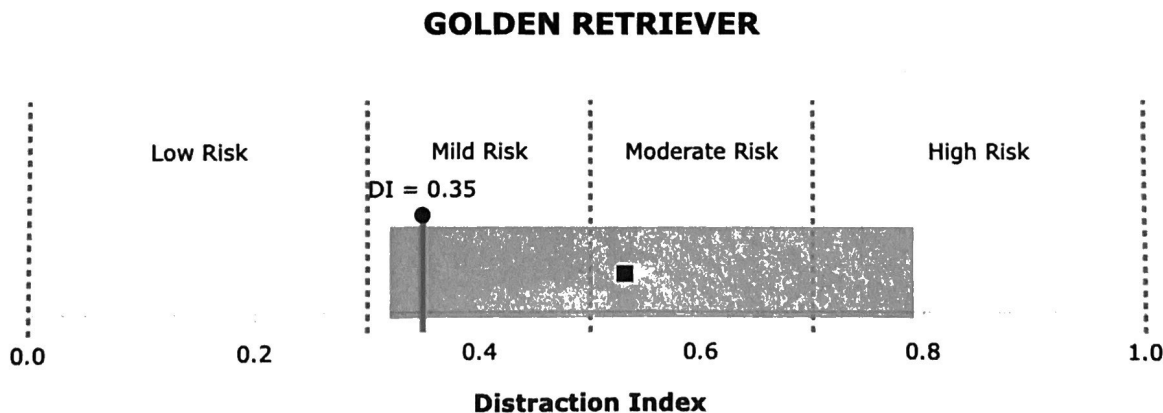
Cavitation/Other Findings: No cavitation present.

Interpretation

Distraction Index (DI): The laxity ranking is based on the hip with the greater laxity (larger DI). In this case the DI used is 0.35.

OA Risk Category: The DI is between 0.31 and 0.49. This patient is at mild risk for hip OA.

Distraction Index Chart:



BREED STATISTICS: This interpretation is based on a cross-section of 25429 canine patients of the GOLDEN RETRIEVER breed in the AIS PennHIP database. The gray strip represents the central 90% range of DIs (0.32 - 0.79) for the breed. The breed average DI is 0.53 (solid square). The patient DI is the solid circle (0.35).